

Effect of Incisor Retraction on the Lips in Patients with Excessive Proclination

Shweta S Nidavani¹, MB Halkati², Shkeel Ahmed Galagali³

Author's Affiliation: ¹Assistant Professor ²Professor and Head ³Reader, Department of Orthodontics, Al-Ameen Dental College, Vijaypur, Karnataka 586108, India.

Corresponding Author: MB Halkati, Professor and Head, Department of Orthodontics, Al-Ameen Dental College Vijaypur, Karnataka 586108, India.

E-mail: drbasavarajc@yahoo.in

Received on 29.04.2019; **Accepted on** 28.06.2019

Abstract

Aim: To study the effect of incisor retraction on the lip position in patients with excessive proclination. *Materials and Method:* pre and post treatment cephalograms 40 adult patients. (26 female and 14 male) pre and post treatment cephalograms of these patients were analysed to compare the effect retraction of incisors on the lip. *Results:* An average retraction of maxillary incisor of 3.5 ± 3.3 mm caused the upper lip to retract by 5.3 ± 1.9 mm.; An average retraction of maxillary incisor of 3.5 ± 3.3 of mm. caused the lower lip to retract by 1.9 ± 1.7 mm. *Conclusion:* Strong correlation existed between upper incisor retraction and lower lip retraction (r- value 0.0479) and lower incisor retraction and lower lip retraction (r-value 0.0641) Ratio of upper incisor retraction to upper lip retraction is 1.5:1. Ratio of upper incisor retraction to lower lip retraction is 1.7:1. Ratio of lower incisor retraction to lower lip retraction is 1.2:1. Ratio of lower incisor proclination to lower lip protrusion is 0.4:1. For 1 mm Upper incisor retraction caused the in the labiomental fold angle increase by 4.1° .

Keywords: Incisor retraction; Proclination; Cephalograms.

How to cite this article:

Shweta S Nidavani, MB Halkati, Shkeel Ahmed Galagali. Effect of Incisor Retraction on the Lips in Patients with Excessive Proclination. Indian J Dent Educ. 2019;12(2):41-44.

Introduction

Orthodontic diagnosis and treatment planning is in a period of remarkable change, away from previous dental occlusion and hard tissue relationship. The transition now is toward soft tissue paradigm; in which primary goal of treatment is to obtain best possible adaption and proportions of soft tissues of face and mouth and secondary goal is functional dental occlusion [6].

The position of the teeth must be established with periodontal health and aesthetics in mind.

The change of most significance to orthodontist

that the lips and other soft tissues of the face. Sag downward with aging.

With aging lips also becomes progressively thinner with less vermilion display [3].

The same thinking applies to wherethe teeth should be placed to support the lips in an adolescent, if the lips are not somewhat prominent when the treatment ends in adolescence; they are likely to appear too thin in the years to come. This must be kept in mind when the retraction of protruding incisors is planned.

A decrease in the fullness of lips is an obvious sign of aging.

It is essential to presume not only the final dental occlusion but also the soft tissues mainly the position of lips which are in direct relation to the teeth.

Rains and Nanda analysed records of 30 post pubertal white females to determine the correlation between maxillary incisor retraction and integument profile changes they found complex interaction between dentitions the bony structures and the perioral soft - tissue profile [5].

An upper lip that inclines backward in relationship to a true vertical line is uneasthetic. Retracting the maxillary incisors reduces the prominence of upper lip, and an important guideline to the orthodontist is that maxillary incisor should not be over retracted to the point that inclination of upper lip to the true vertical line becomes negative [6].

Materials and Methods

Pre and Post treatment cephalograms of 40 adult patients were treated in the Department of Orthodontics and Dentofacial Orthopaedics in Al Ameen Dental College Vijaypur were analysed. All the patients were at least 17yrs of age. All patients were treated with standard MBT philosophy using 022 slot multibonded appliances for correction of Class I or Class II malocclusion.

Inclusion criteria: proclined incisors, treated with extraction of 1st premolars.

Adult patient

No previous orthodontic treatment

No congenitally missing and impacted teeth.

Exclusion criteria: Cases treated by functional and surgical line of treatment.

Patients with systemic diseases.

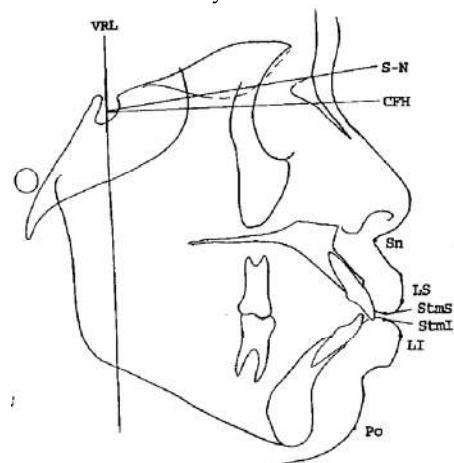


Diagram 1: Soft and Hard Tissue Landmarks

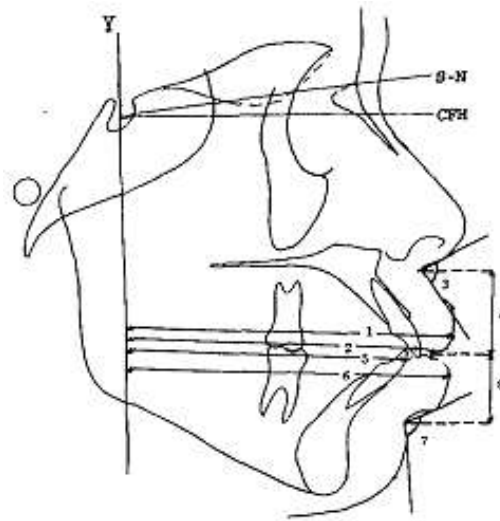


Diagram 2: Angular and Linear Measurement

Horizontal reference (CFH) constructed 7° inferior to sella-nasion was used as X-axis. Vertical reference line (Y) passing through sella and perpendicular to X- axis served as Y- axis.

The following landmarks were identified for the study.

Subnasale (Sn)- The point of convergence of the nose and upper lip.

Superior sulcus (SS)- The point of greatest concavity in the midline between upper lip (LS) and subnasale (Sn) .

Labralesuperius (LS)- The most anterior point on concavity of the upper lip.

Labraleinferius (LI)- The most anterior point on the convexity of the lower lip.

Sulcus inferius (SI)- The point of greatest concavity in the midline between lower lip and soft tissue chin.

Soft tissue pogonion (Po')- the most anterior point on the soft tissue chin.

Stomionsuperius (StmS)- The lower most point of the upper lip.

Stomioninferius (StmI)- The upper most point on the vermillion border of the lower lip.

Upper incisor (U1)- The most anterior point on the crown of maxillary incisor.

Lower incisor (L1)- The most anterior point on the crown of mandibular incisor.

The linear measurements were made from the above listed hard and soft-tissue points to the y-reference plane (Diagram 2).

Statistical Analysis: The mean and standard deviation of the difference between pre and post-treatment for each of soft tissue measurements were calculated. The means for each variable were subjected to paired T-test to determine the significance of change between pre and post treatment. This data was subjected to Pearson correlation analysis. The purpose was to identify the effect of the most important variables used on the significant dependent variables at the level of significance of $p < 0.05$.

Results

Table 1: Dental and soft tissue changes due to mechanotherapy

Ref no.	variable	Ceph point	Mean pre/post difference	P-value
1.	Upper lip retraction	LS-Y	5.3 ± 1.9	$<<0.001$
2.	Upper incisor retraction	U1-Y	3.5 ± 3.3	<0.001
3.	Lip strain	A- Ls	1.6 ± 2.4	<0.05
4.	Lower incisor retraction	L1-Y	-0.9 ± 1.1	NS
			1.9 ± 1.7	NS
5.	Lower lip retraction	L1-Y	1.9 ± 1.7	<0.01
			-2.1 ± 1.2	<0.01
6.	Labiomental angle	LMF	14.4 ± 19.8	<0.05

Table 2: Correlation coefficients (r) for comparison of selected hard- and soft tissue changes

Soft tissue	Hard tissue	r
Upper lip retraction	Upper incisor retraction	0.207
Upper lip retraction	Lower incisor retraction	-0.0166
Lower lip retraction	Upper incisor retraction	0.497
lower lip retraction	Lower incisor retraction	0.641
Labiomental fold	Lower incisor retraction	0.321

Upper lip retraction

The present study showed that orthodontic treatment; an average retraction of maxillary incisor of 3.5 ± 3.3 mm caused the upper lip to retract by 5.3 ± 1.9 mm. (an average of the lip strain of 2.35 mm is also considered in the upper lip retraction) if the lip strain is excluded, then 3.5 ± 3.3 mm of incisor retraction caused the lip to retract by 2.9 mm.

Lower lip retraction

As the lower lip rests on the middle third of the upper incisors; the position of lower lip is also dictated by the position of upper incisors.

The present study showed that orthodontic treatment; an average retraction of maxillary of 3.5 ± 3.3 incisor of mm. caused the lower lip to retract by 1.9 ± 1.7 mm. giving ratio of 1.8:1.

In about 10 patients lower incisors were proclined to achieve the proper overjet, lower incisor proclination of 0.9 ± 1.1 mm caused the lower lip to move ahead by 0.42 mm giving the ration of lower incisor proclination to lower lip moved forward in the ratio of 0.4:1.

Labiomental fold

In about 10 patients lower incisors were retracted to achieve the proper overjet, lower incisor retraction of 1.6 ± 2.4 mm caused the lower lip to move back by 1.9 ± 1.7 mm giving the ration of lower incisor retraction to lower lip moved retraction in the ratio of 1.2:1.

Strong correlation existed between upper incisor retraction and lower lip retraction (r- value 0.0479) and lower incisor retraction and lower lip retraction (r-value 0.0641)

Discussion

Assessment of facial profiles by varying the nose, lip, chin relations by dentists, orthodontists, oral surgeons and pedodontists showed that lip protrusion was acceptable for both males and females when large nose or chin was present. the most favoured female profile exhibited four millimetres more lip protrusion than most favoured male profile [3]. Czarnecki concluded that balance between the size of nose, lips and chin are essential to balance facial appearance. By limiting the sample to adults influence of growth was reduced. Few authors like Russell and Nelson [1] and park *et al.* [2] reported that relationship of soft -tissue reference could not be shown to be directly affected by retraction of incisors because of masking effect of growth.

Summary and Conclusion

Ratio of upper incisor retraction to upper lip retraction is 1.5:1

Ratio of upper incisor retraction to lower lip retraction is 1.7:1

Ratio of lower incisor retraction to lower lip retraction is 1.2:1

Ratio of lower incisor proclination to lower lip protrusion is 0.4:1

For 1mm Upper incisor retraction caused the in the labiomental fold angle increase by 4.1°

Upper incisor retraction caused the significant

changes not only in the upper lip but also in the upper lip, lower lip and labiomental fold.

The lower lip showed the higher correlation to the upper incisor and lower incisor retraction. (r value of 0.497 and 0.641).

Despite the extensive efforts to write quantitative rules for facial aesthetics, at this point it seems clear that Peck and Peck were correct when they stated that "obviously, there is no such thing as the equation of beauty, no numbers or devices can totally express the complexity of facial aesthetics."

Knowing the amount of changes that the orthodontics treatment can be bring about is essential to set the treatment goals to address the patients chief complaint for today but also the future like signs of aging for the youthful appearance.

References

1. Russel DM, Nelson RT. facial soft tissue profile change in north American black with four first premolar extractions. J Md state dental association. 1986;29(1):24-8.
2. Park S, kudlick EM, abrahamian A. vertical dimension changes of lips in north American black patients after four first premolar extraction. Am J Orthod Dentofac Orthop. 1989;96:152-60.
3. Nanda S. kapila S. Growth changes in the soft tissue facial profile. Angle Orthod. 1990 Fall;60(3):177-90.
4. Talass F, Backer RC. Soft tissue profile changes resulting from retraction of maxillary incisors. Am J Orthod Dentofac Orthop. 1987;91:385-94.
5. Rains MD. Nanda R. soft tissue changes associated with maxillary incisor retraction. Am J Orthod Dentofac Orthop. 1982;74:396-404.
6. Ackerman J A. Proffit, W.R Soft tissue limitations in orthodontics: treatment planning guide lines.angle orthodontist. 1997;67(5);327-36.
7. Caplan j. Mark, prassana kumar shivapuja. effect of premolar extraction on soft tissue profile changes in adult African American females. Angle orthod. 1997;67(2):129-36.
8. Russell dm, nelson rt. Facial soft tissue profile changes in north American black with four first premolar extractions. J Md state dental assoc. 1986;29(1)24-8.
9. Park s, kudlick em abrahamian A Vertical dimension changes of the lips in north American black patient after four first premolar extraction. Am J Orthop 1989;96:152-60.
10. RA Holdaway. A soft-tissue cephalometric analysis and its use in orthodontic treatment planning. Part II. Am J Orthod. 1984 Apr;85(4):279-93